

## Combination Therapy with Hydroquinone, Tretinoin and Steroid for Treatment of Melasma in Iraqi patients

Narjes Chyad Abdul-Zahra, M.Sc pharmacology.(assistant lecturer)\*

Ali Tariq Abd Al Hassan, Ph.D,dermatology , (lecturer ) \*\*

University of Kerbala – College of medicine, Department of Pharmacology \*

University of Kerbala – College of medicine, Department of medicine \*\*

(K . J . Pharm . Sci)

(Received July ٢٠١٠ , Accepted Nov. ٢٠١٠)

### Abstract

**Background:** Melasma is one of the most frequently acquired hyperpigmentation disorders clinically characterized by symmetrical brown patches on sun exposed areas. The pathogenesis of melasma is not fully understood, but several hypotheses have been suggested. Patient treatment is particularly difficult and challenging, and necessitates using different modalities of treatment which is a burden on the patient.

**Objectives:** The aim of this study was to evaluate the efficacy of combination of retinoic acid, steroids and hydroquinone in reducing melasma.

**Patients and Methods:** The study was conducted at the private clinic, Kerbala city in the period July ٢٠٠٨- March ٢٠٠٩. One hundred & thirteen patients with melasma were included in this study, all of them were female (pregnant and nursing mothers were excluded), with an age range ٢٥-٤٠ years. Full clinical examination was done for all patients ,the severity of melasma was assessed by the melasma area severity index(MASI).The treatment include using of combination of retinoic acid ٠,٢٥,steroid (hydrocortisone cream ,Betamethasone cream and clobetasol propionate cream ) and hydroquinone in addition to use of sunblock SPF٦٠ regularly for all patients .

The patients divided in to three groups according to primary cause of melasma and the treatment modules were as follow:

Group ١: (sun exposure ) the formula used was retinoic acid ٠,٢٥ ,hydroquinone ٢% and hydrocortisone cream ,for group (٢)(cosmetic ) the formula used was retinoic acid cream ٠,٢٥ ,hydroquinone cream ٤%and betamethasone cream and for group (٣) (pregnancy cause )we used retinoic acid cream ٠,٢٥ ,hydroquinone cream ٤% and clobetasol propionate cream .The follow up and response to treatment recorded every week depending on the MASI until the desired response was achieved at the end of ٤<sup>th</sup> week .follow-up was carried out for ٦ months later to record any relapse.

**Result:** The results revealed marked improvement and significant decrease in MASI in all groups .The MASI for group (١) decrease from ١٠.٦ to reach ٣,١٨,MASI for group (٢) was decreased from ١٥,٥ to ٣,٨٨ while MASI for group (٣) decreased from ٢٢ to reach ٤,٤ .

No side or unwanted effect recorded or informed by the patients .

**Conclusion:** Combination of retinoic acid, steroids and hydroquinone was found to be effective in reducing and treating melasma if used in proper way.

علاج داء الكلف بمركب دوائي مكون من الهيدروكورتون , حامض الرتنويك والاستيرويدات  
 الباحثين : نرجس جواد عبد الزهرة , ماجستير ادوية (مدرس مساعد)\*  
 علي طارق عبد الحسن , دكتوراه جلدية (مدرس)\*\*  
 جامعة كربلاء , كلية الطب , فرع الادوية \*  
 جامعة كربلاء , كلية الطب , فرع الطب \*\*

## الخلاصة

### **الخلفية :**

الكلف هو واحد من الامراض الشائعة, يتميز سريريا ببقع متناضرة سمراء اللون تغطي الوجه وخاصة المناطق المعرضة للشمس فيما يخص اسباب المرض لحد الان هي غير مفهومه بشكل كامل وهناك عدة فرضيات تحاول تفسيره. علاج الكلف يعتبر من الامور الصعبة والتي تحتاج عدد كبير من الادوية المختلفة وهذا يكلف المريض الوقت والمال.

### **الاهداف:**

الهدف من هذه الدراسة هو تقييم فعالية المركب المكون من حامض الرتنويك والاسترويد والهيدروكورتون.

### **المرضى والمنهج :**

تمت الدراسة في عيادة خاصة في مدينة كربلاء للفترة من تموز ٢٠٠٨ ولغاية اذار ٢٠٠٩. شارك في الدراسة مائة وثلاثة عشر مريضا وجميعهم كانوا اناثا , ولقد تم اقصاء الحوامل والمرضعات. كانت اعمار المرضى تتراوح ما بين ٢٥ و ٤٠ سنة. تم فحص المرضى بشكل سريري وتم تحديد درجة الاصابه حسب نظام خاص يعرف ب (MASI) تم تقسيم المرضى الى ثلاثة مجاميع حسب السبب الرئيسي للمرض الى:

- ١-مجموعة (التعرض للشمس): تم استخدام حامض الرتنويك ٠,٢٥ , هيدروكورتون ٢% وهايديروكورتزون كريم.
  - ٢-مجموعة(المواد التجميلية): استخدمت حامض الرتنويك ٠,٢٥ , هيدروكورتون ٤% وبيتاميثازون كريم.
  - ٣-مجموعة(الحمل): استخدمت : حامض الرتنويك ٠,٢٥ , هيدروكورتون ٤% كلوبيتازول وبروبيونيت كريم.
- تم متابعة المرضى كل اسبوعان ولمدة ستة اشهر لتسجيل اي انتكاسه للمرض من جديد.

### **النتائج:**

لقد تم تسجيل تحسن ملحوظ في شدة المرض في كل المجاميع بنسب مختلفة حسب النظام المذكور.

### **الاستنتاج:**

ان المركب المكون من حامض الرتنويك والستيرويد والهيدروكورتون وجد انه فعال في تقليل الكلف وعلاجه اذا تم استخدامه بشكل مناسب لكل حالة.

## Introduction

Melasma, a name derived from the Greek melas, or black, is one of the most common causes of acquired, symmetric hypermelanosis of the face. It is characterized by tan-brown macules and patches with a predilection for areas of the skin exposed to the sun, in particular the cheeks, forehead, upperlip, nose, and chin. Women are more affected than men (female to male ratio, ٩: ١).<sup>١</sup>

Melasma is commonly seen in Latin-American and Asian women, particularly those with IV–V skintypes.<sup>١,٢</sup>

The pathogenesis of melasma is not fully understood, but several hypotheses have been suggested. Increased vascularity in melasma lesions has suggested the role of increased number of enlarged vessels in the development of melasma. Endogenous and exogeneous stimuli such as UV exposure, pregnancy, oral contraceptives, estrogen and progestational hormones, genetic influences, photosensitizing and antiseizure drugs, thyroid abnormalities, psychosomatic factors, hepatic dysfunction, parasites, and cosmetics.<sup>٤-١٠</sup>

Generally, melasma is classified into one of ٣ histologic types: epidermal, dermal, and mixed. However, some also include a fourth type known as Wood's light inapparent.<sup>١١</sup>

Under Wood's light the epidermal type often shows a darkening of color when examined, as the light emitted by Wood's lamp is absorbed by the excess melanin. The dermal type, however, will not show this accentuation.<sup>١١,١٢</sup> The mixed type involves a deposition of melanin in both the epidermis and The dermis and color enhancement with Wood's light is seen in some places of the skin, but not others.<sup>١١</sup>

The treatment of melasma is always difficult, and both patients and dermatologist may feel discouraged even when treated with well-established formulations. Until now, hydroquinone has been considered as the gold standard of treatment with moderate results in ٨٠٪ of patients.<sup>١٣</sup>

Other treatments include tretinoin, kojic acid, glycolic acid, liquiritin & pidobenzone ٤٪.<sup>١٤-١٨</sup> Table ١ summarized drugs used in treatment of melasma.

Regarding the drugs used in our study:

**Hydroquinone:** Hydroquinone is a hydroxyphenolic compound, which inhibits the conversion of DOPA (٣, ٤-dihydroxy-phenylalanine) to melanin through the inhibition of tyrosinase<sup>١٩</sup>. It has been the gold standard for treatment of hyperpigmentation for a number of years. It is also believed to inhibit DNA (Deoxyribonucleic acid) and RNA (ribonucleic acid) synthesis and to induce the degradation of melanosomes and destruction of melanocytes<sup>١٩,٢٠</sup>.

**Tretinoin:** Also known as all-trans retinoic acid (ATRA), topical tretinoin ٠,٠٥-٠,١٪ reduces pigmentation by inhibition of tyrosinase transcription and significant thickening of the granular layer and epidermis as a whole; neither the number of melanocytes is affected, nor is there evidence of melanocyte damage<sup>٢١</sup>.

As compared with phenolic compounds, ATRA has to be applied for a greater length of time — significant lightening becomes evident after ٢٤ weeks. Published clinical trials show a good clinical efficacy of ATRA in monotherapy, but better results are obtained in combination with other compounds, such as hydroquinone and

corticosteroids<sup>(٢٢, ٢٣)</sup> The most common side-effects are erythema, peeling, burning and stinging. It should be emphasized that the use of total sun block is mandatory during the ATRA treatment. Other retinoids used in the treatment of melasma include isotretinoin, tazarotene and adapalene<sup>٢١</sup>.

**Steroids:** A range of topical corticosteroids have been used in the treatment of melasma and other hyperpigmentary disorders. Mild steroids

(hydrocortisone ١%) have been used with poor results<sup>(٢٣)</sup>, while potent (Betamethasone ٢%) and very potent steroids (clobetasol propionate ٠,٠٥%) gave better results, as they have a better efficacy when combined with tretinoin or hydroquinone<sup>(٢٤, ٢٥)</sup>. The adverse effects of topical steroids are those typical of their long-term use; atrophy, itching, acne, and telangiectasias, especially frequent in areas more susceptible to local steroid damage (e.g. the face).

Table ١. The mechanisms by which various treatments for melasma achieve their depigmenting effect

Mechanism of action	Therapy
Tyrosinase inhibitor	Hydroquinone Tretinoin* Azelaic acid Kojic acid
Nonselective suppression of melanogenesis	Corticosteroids
Inhibition of ROS**	Azelaic acid
Removal of melanin	Chemical peels
Thermal damage	Laser treatments

\*Tretinoin may also disperse keratinocyte pigment granules and accelerate epidermal turnover.

\*\*ROS, Reactive oxygen species.

## Patients and Methods

Patients were females, aged ٢٥-٤٠ years, with Fitzpatrick skin types III-V and moderate to severe bilateral and symmetric epidermal melasma, easily noticeable and all patients gave informed consent.

One hundred & thirteen patients randomly selected, all of them completed the study, diagnosed clinically as melasma by dermatologist in Karbala city ٢٠٠٨-٢٠٠٩ and treated and followed for ٤ weeks. Their age average was (٣٢,٥ year).

The causes of melasma was as follow: ٤٠ women over ١/٣ (٣٥,٣٩%), the primary cause for melasma was pregnancy, ٣٥ women over ١/٣ (٣٠,٩٧%) the primary cause was abuse of cosmetics (over the counter), ٣٨ women over ١/٣ (٣٣,٦٢%)

the primary cause was regular exposure to sun as shown in (Table ٢, Figure ١).

Drugs used in our trial was retinoic acid cream ٠,٢٥%, hydroquinone cream ٢ & ٤%, hydrocortisone cream ١%, Betamethasone cream ٢%, clobetasol propionate ٠,٠٥%. In addition to the sunblock (spf ٦٠).

The treatment modules were as follow:

- For group ١ (sun exposure) the formula used

Retinoic acid ٠,٢٥ + hydroquinone ٢% + hydrocortisone cream ١% & sunblock regularly

Retinoic acid ٠,٢٥ + hydroquinone ٤% + hydrocortisone cream ١% & sun block regularly

- For group (٢) (cosmetic misuse) the formula used :Retinoic acid

- ٠,٢٥ + hydroquinone ٤% + betamethasone cream ٢% & sunblock regularly.
- For group (٣) ,(pregnancy cause) ,the formula used was :

Retinoic acid ٠,٢٥ + hydroquinone ٤% + clobetasole propionate cream ٠,٠٥% & sunblock regularly.

Melasma severity is scored using the Melasma Area and Severity Index (MASI). In this system, the face is divided into four areas — forehead, right malar, left malar and chin — which correspond, respectively, to ٣٠%, ٣٠%, ٣٠% and ١٠% of the total facial area. The melasma in each of these areas is graded according to three variables: the percentage of total area involved on a scale from ٠ (no involvement) to ٦ (٩٠–١٠٠%; full involvement); darkness scoring from ٠–٤ .

■Scale ٠: no melasma

## Results

For group (١) ,the result revealed slight decrease in hyperpigmentation in the first week and MASI decreased to ٩,٥٤ ,there was clear difference and decrease in colour and size of spot in the second week the MASI decrease to ٧,٩٥ .

In the third week the MASI decreased to ٥,٣ with marked fading and decrease in size and color of spot, and in the last week the MASI decreased to ٣,١٨ with fading of spot ,no side effect noticed or recorded and the patient were greatly satisfied with this result.

The average MASI score before treatment for group (١) was ١٠,٦ ,whereas after ٤ weeks of treatment the MASI score changed to ٣,١٨ ,so the average decrease in the MASI score was ٧,٤٢ ,this represent ٧٠% (table ٣,figure ٢)

For group (٢) cosmetic abuse, there was slight decrease and fading of spot colour and size during the first week, the MASI decreased to ١٣,٩٥ .In the second week

■Scale ١: light brown

■Scale ٢: brown

■Scale ٣: dark brown

■Scale ٤: black.

The MASI is then calculated using the following equation:

MASI = ٠,٣(DF + HF) AF + ٠,٣(DMR + HMR)

AMR + ٠,٣(DML + HML) AML + ٠,١(DC + HC) AC

Where D is darkness, H is homogeneity, A is area, F is the forehead, MR is the right malar, ML is the left malar, and C is the chin. The values ٠.٣, ٠.٣, ٠.٣ and ٠.١ signify the

respective percentages of total facial area. MASI was measured before treatment as a baseline and every week during treatment<sup>٧٧</sup>.

Regarding the statistical methods, we use SPSS program (version ١٤) to get our results

there was obvious decrease in size of spot, the fading obvious with irregular of shape and size and MASI decreased to ١١,٩٢ .In third week the MASI decreased to ٧,٧٥ and the fading was more obvious. In the fourth week there was a marked decrease in size of spot and clear fading, the MASI decreased to ٣,٨٨, no sign of side effect or other discomfort observed or informed by the patients.

The average MASI score before treatment for group (٢) was ١٥,٥ ,whereas after ٤ weeks of treatment the MASI score changed to ٣,٨٨ ,so the average decrease in the MASI score was ١١,٦٢ ,this represent ٧٤,٩٦% decrease and was statistically significant ( $p=٠,٠٥$ ) (table ٣,figure ٣).

For group (٣), the MASI decreased to ١٩,٨٨ during the first week of treatment with slight, but obvious fading of spots colour. In the second week there was

more fading of spots and MASI decreased to ١٦,٥. The MASI decreased to ٦,٦ in the third week of treatment with clear fading of spots and decrease in size, no sign of allergy or any complication. In the fourth week the spots faded totally with clear face and MASI decrease to ٤,٤.

The average MASI score before treatment for group (٣) was ٢٢, whereas after ٤ weeks of treatment the MASI score changed to ٤,٤, so the average decrease in the MASI score was ١٧,٦

### **Discussion**

Melasma is an acquired irregular brown or sometimes gray brown hyperpigmentation of the face and occasionally the neck, usually occurring in women.

Although melasma is primarily associated with pregnancy and oral contraceptive pills consumption, other influences such as genetic, racial, endocrine and cosmetic factors seem to be involved. It is generally accepted that sunlight and genetic factors play major roles in the pathogenesis of this condition.<sup>٤, ٢٨</sup>

Therapy for melasma should begin with the identification and elimination of causative factors such as drugs (oral contraceptive, hormone-containing drugs and photosensitizing drugs), cosmetics and sunlight. Avoidance of solar exposure and use of a high-potency broad-spectrum sunscreen are the most effective measures. If sun exposure is not reduced, other therapy will often fail. Current treatments include hypopigmenting agents, chemical peels and recently laser therapy.<sup>٤, ٢٨</sup>

Hypopigmenting agents include phenolic and nonphenolic derivatives. Phenolic agents include hydroquinone, which is used alone or in combination with

,this represent ٨٠% decrease and was statistically significant (p=٠,٠٥)(table ٣,figure ٤)

All the patients informed by gradual withdrawal of steroids & the treatment last for several months when keeping retinoic acid and hydroquinone. After two months later the spots faded totally, no unwanted effects or allergy as informed by patients and were greatly satisfied with results; as shown in Table ٤ which shows the patients who reached score ٠-١

retinoids, corticosteroids or other chemicals.<sup>٢٩</sup>

In our study, we used combination therapy in different formulation according to the causative agent and the context of the patient.

We discuss the treatment with patient and get effective communication with them, regarding their expectation of getting free of this disfiguring discoloration of their face.

Patient compliance increased, which is the direct result of understanding their illness from their perspective, this is one of the major thing which enhance their attachment to the prescribed regime. So all the patients completed the trial successfully, and satisfied with the result reached by end of this therapeutic trial.

This clinical trial demonstrates that addition of tretinoin and betamethasone to a cream containing hydroquinone further improves the usefulness of hydroquinone in reducing melasma. This combination product is indicated for the short-term treatment of moderate to severe melasma of the face with use of sunscreen.

Compounded preparations are often effective in patients that have failed to respond to lower concentrations of hydroquinone. With controlled use and

monitoring, side effects from these preparations have proved to be minimal.

A comparative study has recently been completed involving ٤% HQ and the triple fixed combination therapy hydroquinone (HQ) ٤%, retinoic acid RA ٠,٠٥%, and fluocinolonone acetonide (FA)

٠,٠١%. The proportion of patients who considered that the treatment was "excellent" was greater for triple therapy (٥٠%) than for HQ (٣٤%).<sup>٣٠</sup>

The same thing applied to our study were the results were highly accepted by the patients regarding the triple module of treatment

**Conclusion:** Combination of retinoic acid, steroids and hydroquinone was found to be effective in reducing and treating melasma if used in proper way and tailored according the etiological context of the disease.

We recommend also, taking into consideration the perspective of the patient, and giving attention to their suffering of this highly disturbing of their quality of life and social relationship. This psychological support enhance their compliance which is essential for success of any therapeutic intervention.

Table (٢) number of patients involved in the study according to primary cause

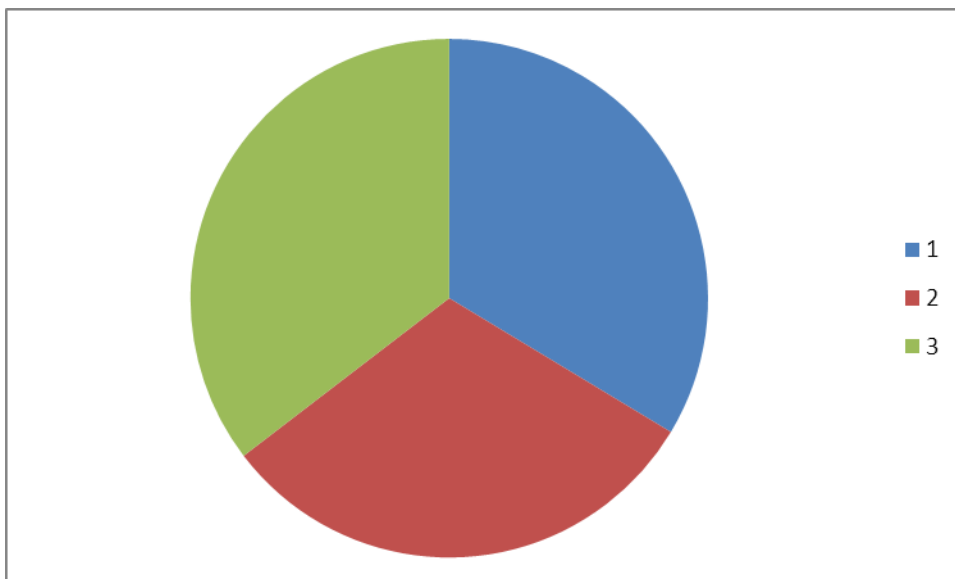
Groups	No of patients involved in the study	Primary cause	Percent
Group ١	٣٨	Regular exposure to sun	٣٣,٦٢
Group ٢	٣٥	Cosmetic	٣٠,٩٧
Group ٣	٤٠	Pregnancy	٣٥,٣٩

Table (٣) MASI score before and after treatment for all groups

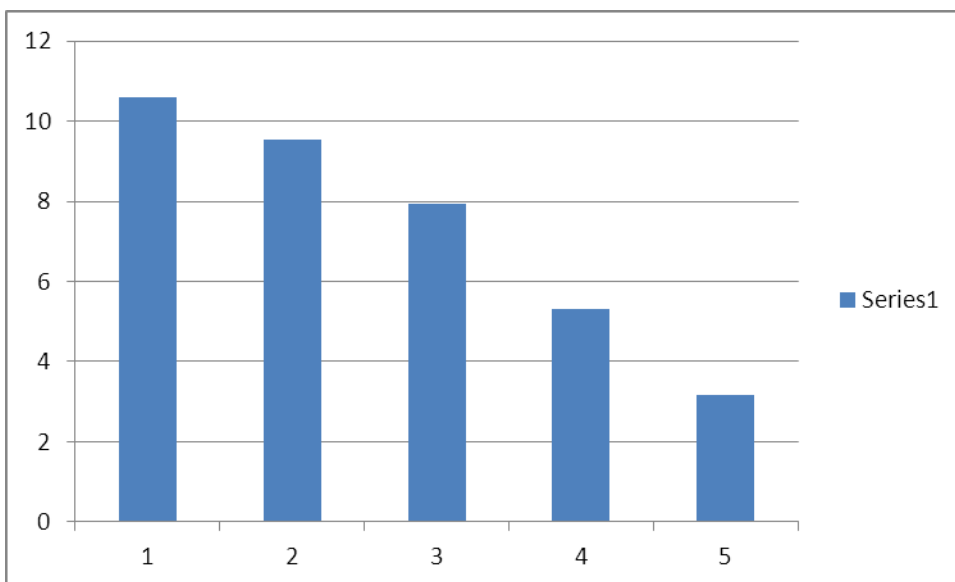
Groups	No of patients	MASI before treatment	MASI after ١ week	MASI after ٢ week	MASI after ٣ week	MASI after ٤ week
Group ١	٣٨	١٠,٦	٩,٥٤	٧,٩٥	٥,٣	٣,١٨
Group ٢	٣٥	١٥,٥	١٣,٩٥	١١,٦٢	٧,٧٥	٣,٨٨
Group ٣	٤٠	٢٢	١٩,٨	١٦,٥	٦,٦	٤,٤

Table (٤) Number of patients who reached color score of ٠-١

Groups	No of patients	Percentage	Duration of treatment
Group ١	٣٨	١٠٠%	٧ weeks
Group ٢	٣٠	٨٥,٧١	٨ weeks
Group ٣	٣٥	٨٧,٥	١٠ weeks



**Figure (١) show the numbers of patients involved in the study for each group**



**Figure (٢): MASI for group (١) before and after treatment**



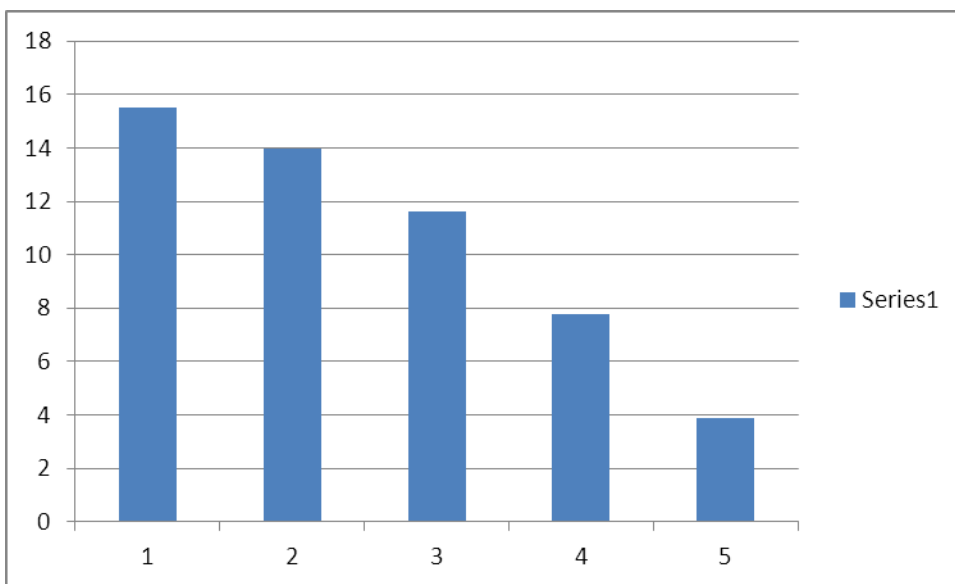


Figure (٣) MASI for group (٢) before and after treatment

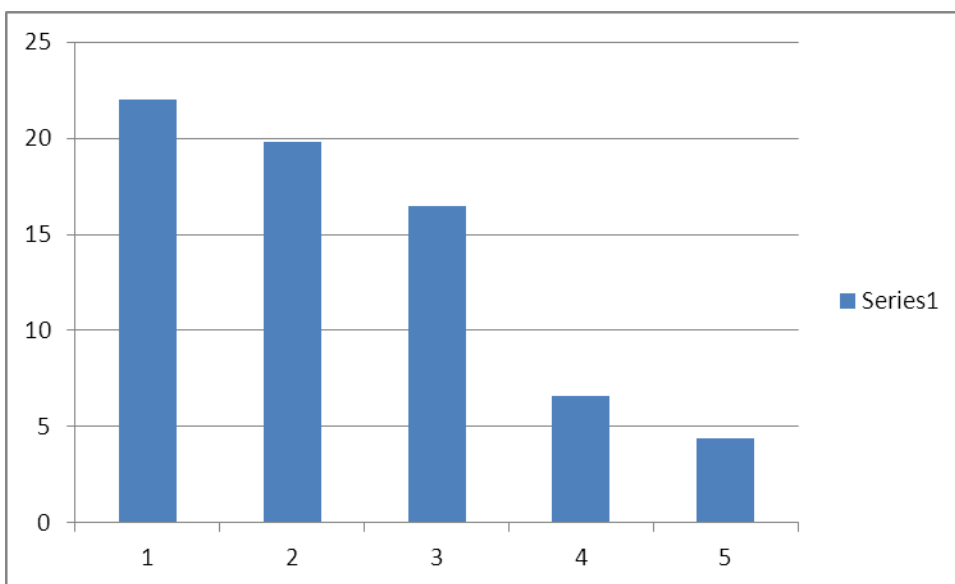


Figure (٤) MASI for group (٣) before and after treatment

**References**

- ١- Guevara IL, Amit GP..IntJ Dermatol ٢٠٠٣; ٤٢, ٩٦٦-٩٧٢
- ٢- Javaheri SM, Handa S, Kaur I, et al. Int J Dermatol ٢٠٠١; ٤٠: ٣٥٤-٣٥٧.
- ٣- Vazquez M, Maldonado H, Benaman C, et al. Int J Dermatol ١٩٨٨; ٢٧: ٢٥-٢٧.
- ٤- Grimes PE. Melasma: Arch Dermatol ١٩٩٥; ١٣١: ١٤٥٣-١٤٥٧.
- ٥- Kauh YC, Zachian TF. Adv Exp Med Biol ١٩٩٩; ٤٥٥: ٤٩١-٤٩٩.
- ٦- Piamphongsant T. Int J Dermatol ١٩٩٨; ٣٧: ٨٩٧-٩٠٣.
- ٧- Niepomniscz H, Amad RH. Endocrinol Invest ٢٠٠١; ٢٤: ٦٢٨-٦٣٨.
- ٨- Resnik S. Am Med Assoc ١٩٦٧; ٩٩: ٩٥-٩٩.
- ٩- Maeda K, Naganuma M, Fukuda M, et al..Pigment Cell Res ١٩٩٦; ٩: ٢٠٤-٢١٢.
- ١٠- Sanchez NP, Pathak MA, Sato S, et al. J Am Acad Dermatol ١٩٨١; ٤: ٦٩٨-٧١٠.
- ١١- Gilchrist BA, Fitzpatrick TB, Anderson RR, Parrish JA. Br J Dermatol ١٩٧٧; ٩٦: ٢٤٥-٨
- ١٢- Nordlund JJ, Boissy RE, Hearing VJ, King RA, Ortonne JP, editors. New York: Oxford University Press; ١٩٩٨.
- ١٣- Vazquez M, Sanchez JL. Cutis ١٩٨٣; ٣٢: ٩٢-٩٦.
- ١٤- Guevara JL, Pandya AG. Int J Dermatol ٢٠٠١; ٤٠: ٢١٠-٢١٥.
- ١٥- Candance K, Kimbrough-Green DK, Christopher EM, et al. Arch Dermatol ١٩٩٤; ١٣٠: ٧٢٧-٧٣٣.
- ١٦- Lawrence N, Cox SE, Brody HJ. Am Acad Dermatol ١٩٩٧; ٣٦: ٥٨٩-٥٩٣.
- ١٧- Amer M, Metwalli M. Int J Dermatol ٢٠٠٠; ٣٩: ٢٩٩-٣٠١.
- ١٨- Zanieri F, Assad GB, Campolmi P, Lotti T. Dermatol Ther ٢٠٠٨; ٢١ Suppl ١: S١٨-٩
- ١٩- Palumbo A, d'Ischia M, Misuraca G, Prota G. Biochim Biophys Acta ١٩٩١; ١٠٧٣: ٨٥-٩٠.
- ٢٠- Ennes SBP, Paschoalick RC, De Avelar M, Alchorne M. J Dermatol Treat ٢٠٠١; ١١: ١٧٣-٩
- ٢١- Roméro C, Aberdam E, Larnier C, Ortonne JP. J Cell Sci ٢٠٠٢; ١٠٧(Pt ٤): ١٠٩٥-١٠٣
- ٢٢- Ortonne JP. Dermatol Ther ٢٠٠٦; ١٩(٥): ٢٨٠-٨
- ٢٣- Torok HM. Am J Clin Dermatol ٢٠٠٦; ٧(٤): ٢٢٣-٣٠
- ٢٤- Gupta AK, Gover MD, Nouri K, Taylor S. J Am Acad Dermatol ٢٠٠٦; ٥٥(٦): ١٠٤٦-٦٥
- ٢٥- Bandyopadhyay D. Indian J Dermatol ٢٠٠٩; ٥٤(٤): ٣٠٣-٩
- ٢٦- Kligman AM, Willis I. Arch Dermatol ١٩٧٥; ١١١: ٤٠-٨.
- ٢٧- Nakayama H, Harada R, Toda M. Int J Dermatol ١٩٧٦; ١٥(٩): ٦٧٣-٥
- ٢٨- Katasambas A, Antoniou CH. J Eur Acad Dermatol Venerol ١٩٩٥; ٤: ٢١٧-٢٢٣.
- ٢٩- Sanchez JL, Vazquez M. J Dermatol ١٩٨٢; ٢١: ٥٥-٥٨.
- ٣٠- Haddad AL, Matos LF, Brunstein F, Ferreira LM, Silva A, Costa D. Int J Dermatol ٢٠٠٣; ٤٢: ١٥٣-٦.